



Journal of Postgraduate Medicine

Official Publication of
The Staff Society of the Seth GS Medical College and KEM Hospital, Mumbai, India

When potion becomes poison! A case report of flecainide toxicity

Bajaj S, Tullu MS, Khan ZAH, Agrawal M

Department of Pediatrics,
Seth Gordhandas
Sunderdas Medical
College and King Edward
Memorial Hospital,
Mumbai, Maharashtra,
India

Address for correspondence:

Dr. Milind S Tullu,
E-mail: milindtullu@
yahoo.com

Received : 19-06-2016
Review completed : 22-09-2016
Accepted : 03-01-2017

ABSTRACT

We report a 48-day-old female infant, who developed cardiac conduction abnormalities and seizures secondary to supratherapeutic doses of oral flecainide. Flecainide was started in this infant for treatment of supraventricular tachycardia. The drug was withdrawn with successful normalization of the QRS complex and no further recurrence of seizures. The Naranjo probability score for adverse drug reaction was 8, making the causality “probable.” The case restates an important message that physicians should be aware of the side effects of the drugs that they prescribe, especially of those drugs which have a narrow therapeutic window.

KEY WORDS: Arrhythmias, cardiac, drug-related side effects, flecainide, infant, seizures

Introduction

Flecainide is a potent antiarrhythmic agent with a narrow window of safety.^[1] Dosage errors leading to drug toxicity have been reported in the past.^[2-4] Our case of flecainide toxicity manifested with cardiac conduction abnormalities and the rarer neurotoxicity, following a dose which was only 1.7 times the upper recommended dose.

Case Report

Our patient was a 48-day-old female infant, who presented with a history of convulsions 1 day before indoor admission. On eliciting a detailed history, it was suspected that the convulsions were probably secondary to drug toxicity. The case summary of the infant is presented in Table 1. The infant developed seizures following the 7th oral dose of flecainide at 1.7 times the recommended upper limit. On presentation to us, following

the 9th supratherapeutic dose, the infant had prolonged QRS complexes too [Figure 1a]. The QRS complex normalized following the withdrawal of the drug within 3 days [Figure 1b], and there were no further seizures in the infant [Table 1]. There was no history of sudden stoppage of milk feeds before the onset of the seizures. The Naranjo probability score for adverse drug reaction was 8, making the causality “probable.”

Discussion

In infants without an underlying structural heart disease, the first-line drugs for supraventricular tachycardia (SVT) include digoxin and propranolol.^[5] Flecainide is a second-line agent for refractory SVT^[5] though its use in children is considered to be off-label. A recent study done by Ferlini *et al.* documents the successful use of flecainide even as a first-line drug in newborns with SVT.^[6]

Access this article online	
Quick Response Code:	Website: www.jpgmonline.com
	DOI: 10.4103/0022-3859.201422

This is an open access article distributed under the terms of the Creative Commons Attribution-NonCommercial-ShareAlike 3.0 License, which allows others to remix, tweak, and build upon the work non-commercially, as long as the author is credited and the new creations are licensed under the identical terms.

For reprints contact: reprints@medknow.com

How to cite this article: Bajaj S, Tullu MS, Khan Z, Agrawal M. When potion becomes poison! A case report of flecainide toxicity. J Postgrad Med 2017;63:265-7.

Table 1: Time-related events in the case history

Age of the infant in days	Relevant clinical and investigational details
38	Irritability, increased respiratory effort, poor feeding. Weight - 3.8 kg
40	Progressively increasing respiratory distress, altered sensorium, and shock Child intubated in a private hospital ECG revealed SVT with AVRT with RBBB. Reverted with injectable adenosine in correct dosage Following reversion of the SVT, injectable metoprolol and injectable amiodarone were administered in appropriate dosage for 3 days
44	Oral flecainide started at 10.2 mg/kg/day in two divided doses (1.7 times the recommended upper limit, i.e., 6 mg/kg/day) Mother was instructed to divide each tablet of flecainide (50 mg) into two equal parts manually, crush the tablet manually and dissolve it in 2.5 ml of sterile water (10 mg/ml) and administer 2 ml of the resultant solution to the baby (20 mg), twice a day Discharged the next day from the private hospital
47	After the seventh dose of oral flecainide, the infant developed generalized tonic seizures lasting for 5 min, resolved spontaneously, with postictal drowsiness Admitted to a private hospital Preliminary investigations (complete blood counts, serum electrolytes, cerebrospinal fluid analysis) - normal Unsuspecting, no changes made in the existing prescription of ongoing high-dose flecainide
48	Shifted to our center (ninth dose of flecainide administered) Infant stable hemodynamically, normal sensorium. Normal clinical examination. MRI brain - normal Detailed review of records alerted about the possibility of flecainide overdose ECG - broad QRS complexes (0.20 s) [Figure 1a] Flecainide withdrawn completely Daily ECG - to monitor the QRS interval (flecainide effect on cardiac conduction)
51	Complete normalization of the ECG [Figure 1b]
54	Amiodarone started orally at 400 mg/1.73 m ² /day in two divided doses after ensuring normal thyroid function on the 6 th day after stopping oral flecainide Flecainide not reintroduced
58	Infant discharged from the hospital
90	Asymptomatic; thriving well Neurological examination normal Gaining milestones normally Compliant with medications

ECG: Electrocardiography, SVT: Supraventricular tachycardia, AVRT: Atrioventricular reentrant tract, RBBB: Right bundle branch block, MRI: Magnetic resonance imaging

Flecainide is a drug with narrow therapeutic range,^[1] the recommended starting dose in infants being 2 mg/kg/day in two to three divided doses,^[6] with the maximum upper limit described at 6 mg/kg/day, administered orally.^[2] Analogous to our

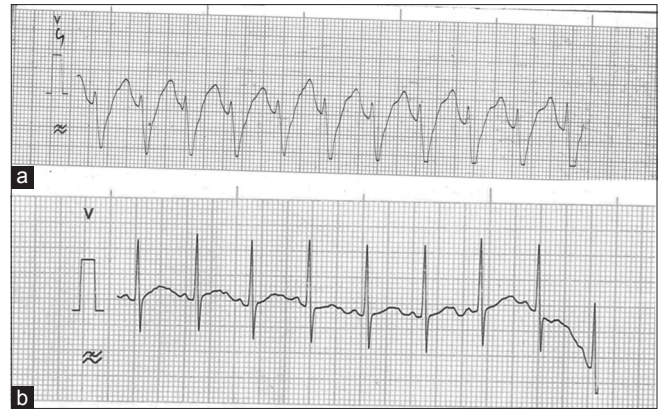


Figure 1: (a) Lead V4; broad QRS complex (0.20 s) after 9 oral doses of flecainide at 1.7 times the recommended upper limit. (b) Lead V4; complete reversion of the electrocardiogram abnormalities. Normal electrocardiogram findings on the 3rd day after stopping flecainide completely

case, at doses as precariously close as two times the upper limit, serious toxicities have been reported in infants.^[2] Milk is known to interfere with the absorption of flecainide. Thus, sudden stoppage of milk feeds has been reported to be responsible for the precipitation of flecainide toxicity in the past;^[7] an aspect absent in our case. The cardiac manifestations of flecainide toxicity (paradoxically) include proarrhythmic effects which are exaggerated in the presence of an underlying structural heart disease.^[1,6] The neurotoxicity, though rarer than the hemodynamic toxicity, is manifested by seizures, myoclonus, hallucinations, diplopia, dizziness, and confusion.^[3] Flecainide has a long plasma half-life of 12–27 h and takes 3–5 days for a steady state.^[1,6] This increases the potential of side effects in the eventuality of an overdose. Although the literature records cases of flecainide toxicity in infancy, our infant is one of the youngest to be reported, with the exception of an 18-day-old neonate reported by Jang *et al.*^[4]

Oral formulations for flecainide in India include tablets only, with the lowest available power being 50 mg/tablet. The correct administration of small doses in infants necessitates correct calculations, crushing and diluting the tablet, and dispensing it through the syringe or a precalibrated dispenser.^[8] These steps are potential loopholes for serious dosage errors occurring during drug administration;^[8] more so, when the mother herself has been instructed to crush, dilute, and administer the drug, as in our case. In countries like ours, where therapeutic drug monitoring for flecainide is not available, monitoring the QRS interval is a surrogate, and an inexpensive method to keep a check on the drug's efficacy and the cardiac conduction safety.^[1] Widening of the QRS complex more than 25% above the baseline value is an indicator to reduce the dose of the drug.^[1] In our patient, the QRS complex measured 0.20 seconds (for 98th percentile of 0.07 seconds, and a mean reference value of 0.05 seconds); a clear indicator of the cardiac toxicity. Although sodium bicarbonate has been advocated as an antidote in flecainide toxicity,^[2,4] there are cases which have failed to show a significant effect of the drug in improving the QRS interval,^[2] especially in asymptomatic cases with only mild

to moderate QRS prolongation.^[2] In the current case, since the infant was asymptomatic and hemodynamically stable when she presented, a conservative method of management was chosen; with success.

In the current case, the Naranjo probability score for adverse drug reaction was 8, making the causality “probable.” The drug was not readministered; neither placebo was given nor the drug level in the blood/body fluids was tested. Since this was the first case of the toxicity in the infant, we cannot comment on whether there were similar episodes in the past. These make an underscoring of the Naranjo scale in our case, highly possible. It may be noted that any score of 9 or above on the Naranjo scale indicates a “definite” association.^[9]

In conclusion, our case is unique since it reports a very young infant with flecainide toxicity at a very small supratherapeutic dose. The case highlights the importance of being aware of the adverse drug effect of every prescribed drug, importance of correct dosage, availability of appropriate formulations, potential dangers of incorrect prescriptions, and high vigilance in case of drugs with a narrow therapeutic index.

Financial support and sponsorship

Nil.

Conflicts of interest

There are no conflicts of interest.

References

1. Tamargo J, Le Heuzey JY, Mabo P. Narrow therapeutic index drugs: A clinical pharmacological consideration to flecainide. *Eur J Clin Pharmacol* 2015;71:549-67.
2. Close BR, Banks CJ. Pediatric flecainide toxicity from a double dose. *Am J Emerg Med* 2012;30:2095.e1-2.
3. Ghika J, Goy JJ, Naegeli C, Regli F. Acute reversible ataxo-myoclonic encephalopathy with flecainide therapy. *Schweiz Arch Neurol Psychiatr* 1994;145:4-6.
4. Jang DH, Hoffman RS, Nelson LS. A case of near-fatal flecainide overdose in a neonate successfully treated with sodium bicarbonate. *J Emerg Med* 2013;44:781-3.
5. Kohli V. Oral flecainide is effective in management of refractory tachycardia in infants. *Indian Heart J* 2013;65:168-71.
6. Ferlini M, Colli AM, Bonanomi C, Salvini L, Galli MA, Salice P, *et al.* Flecainide as first-line treatment for supraventricular tachycardia in newborns. *J Cardiovasc Med (Hagerstown)* 2009;10:372-5.
7. Russell GA, Martin RP. Flecainide toxicity. *Arch Dis Child* 1989;64:860-2.
8. Chedoe I, Molendijk HA, Dittrich ST, Jansman FG, Harting JW, Brouwers JR, *et al.* Incidence and nature of medication errors in neonatal intensive care with strategies to improve safety: A review of the current literature. *Drug Saf* 2007;30:503-13.
9. Naranjo CA, Busto U, Sellers EM, Sandor P, Ruiz I, Roberts EA, *et al.* A method for estimating the probability of adverse drug reactions. *Clin Pharmacol Ther* 1981;30:239-45.